31 Dermatitis Herpetiformis and Linear IgA Bullous Dermatosis

Bridget E. Shields, Christopher M. Hull and John J. Zone

Key features

- Dermatitis herpetiformis (DH) is differentiated from linear IgA bullous dermatosis (LABD) on the basis of granular IgA versus linear IgA deposition at the basement membrane zone, as observed by direct immunofluorescence
- DH is a cutaneous manifestation of celiac disease (CD) and is associated with gluten sensitivity in virtually all cases
- DH and CD are genetic disorders strongly associated with HLA-DQ2 and DQ8 genotypes
- CD-associated IgA antibodies are directed against *tissue* transglutaminase (transglutaminase 2 [TG2]); IgA antibodies in the skin of DH patients are directed against *epidermal* transglutaminase (transglutaminase 3 [TG3])
- The intestinal and cutaneous disease in DH can be controlled by gluten restriction; both DH and LABD respond to sulfone therapy
- In adults, LABD is often drug-induced

DERMATITIS HERPETIFORMIS

Synonym: ▪ Duhring disease

Introduction

Dermatitis herpetiformis (DH) is a cutaneous manifestation of gluten sensitivity. Although over 90% of DH patients have evidence of a gluten-sensitive enteropathy (GSE), only about 20% have intestinal symptoms of celiac disease (CD). Both the skin disease and the intestinal disease respond to gluten restriction and recur with institution of a gluten-containing diet.

Four findings support the diagnosis of DH:

- pruritic papulovesicles or excoriated papules on extensor surfaces
- neutrophilic infiltration of the dermal papillae with vesicle formation at the dermal–epidermal junction
- granular deposition of IgA and epidermal transglutaminase (TG3) within the dermal papillae of clinically normal-appearing skin adjacent to a lesion
- a response of the skin disease, but not the intestinal disease, to dapsone therapy.

Although DH is usually a lifelong condition, the course may wax and wane. A spontaneous remission may occur in up to 10% of patients, but most clinical remissions are related to dietary gluten restriction[1].

History

Dr Louis Duhring described DH at the University of Pennsylvania in 1884. It was the first skin disease described by an American dermatologist. The critical discoveries in our understanding of DH are listed in Table 31.1.

Epidemiology

DH occurs more commonly in people of northern European origin. It is uncommon in African-Americans and Asians. The annual incidence ranges from 0.4–3.5/100 000 and appears to be declining, likely secondary to better recognition of early celiac disease[2]. The mean age of onset is during the fourth decade, but it may first appear from age 2 to 90 years. Although adolescent and prepubescent children in the US and northern Europe are infrequently affected, this age group is more commonly affected in other countries such as Hungary and Italy. In most epidemiologic studies, DH occurs more frequently in men, in a ratio of 1.1 : 1 to 1.9 : 1[3]. From 1979 to 1996, the familial incidence of DH in Finland was studied prospectively. DH was diagnosed in 1018 patients and 10.5% of these patients had one or more affected first-degree relatives[4].

A study in Utah (1987) found a prevalence of 11.2 per 100 000. The annual incidence during the years 1978 to 1987 was 0.98 per 100 000. Mean age of onset for men was 40 years and for women was 36 years. The male-to-female ratio was 1.44 : 1[5].

Pathogenesis

Our knowledge of the pathogenesis of DH is based on a number of clinical and laboratory observations. The key observations that have been integrated into theories of pathogenesis are:

- a strong genetic association with HLA DQ2 haplotype and less often DQ8

DERMATITIS HERPETIFORMIS – HISTORIC LANDMARKS	
1884	Louis Adolphus Duhring of Philadelphia described in detail "dermatitis herpetiformis" (DH)
1888	Jean Louis Brocq of Paris renamed the condition "dermatite polymorphe prurigineuse"
1890	T Caspar Gilchrist outlined the histologic changes of DH, which were included in the 1897 edition of Duhring's textbook *Cutaneous Medicine: A Systemic Treatise on Diseases of the Skin*
1940	Sulfapyridine was reported to be an effective treatment for DH. The clinical response to sulfapyridine became a diagnostic test
1950	Dicke, a Dutch pediatrician, observed that patients with celiac disease (CD) improved during World War II when bread was in short supply, and their disease worsened when grain supplies were restored
1953	Diamino-diphenyl sulfone (dapsone), the parent compound of sulfapyridine, also proved to be effective in DH
1967	Independent accounts connected DH with CD
1969	JB van der Meer demonstrated IgA deposits in the papillae of uninvolved skin in DH
1972	Stephen Katz linked DH to the HLA-B8 antigen. This strengthened the association between CD and DH
1986	IgA class anti-endomysial antibodies discovered to be highly specific for DH and CD
1997	DH and CD found to have a common immunogenetic background with strict association with HLA alleles DQ A1*0501 and B1*02, which encode HLA-DQ2 heterodimers
2003	Sardy and colleagues identified epidermal transglutaminase as an autoantigen in DH
2012	Zone and colleagues demonstrated that transfer of DH sera or goat anti-human epidermal transglutaminase antibodies to human skin-grafted mice mimics DH immunopathology

Table 31.1 Dermatitis herpetiformis – historic landmarks.

Downloaded for Anonymous User (n/a) at Egyptian Knowledge Bank from ClinicalKey.com by Elsevier on March 10, 2024. For personal use only. No other uses without permission. Copyright ©2024. Elsevier Inc. All rights reserved.

- some degree of GSE on small bowel biopsy in virtually all patients, accompanied by a TG2-targeted immune response in the intestine in both CD and DH plus an additional anti-TG3 response in DH
- granular IgA deposition within the papillary dermis of the skin (this is essential for the diagnosis and occurs at the site of eventual inflammation)
- neutrophilic infiltration into the dermal papillae
- improvement of symptoms with dapsone therapy and worsening of symptoms with inorganic iodide ingestion.

Genetic predisposition

Specific HLA DQ2 or DQ8 genes, which encode molecules that interact with T cell receptors, are believed to provide the antigenic specificity that processes the gliadin antigen in genetically susceptible individuals. This HLA association is the same for patients with CD and DH. Genes encoding the DQ2 (A1*0501, B1*02) heterodimer are carried by 90% of CD and DH patients, while genes encoding the DQ8 (A1*03, B1*03) heterodimer are carried by the remaining DH patients[6]. Previous descriptions of associations with HLA-B8, as well as HLA-DR3 and HLA-DR5/DR7, represent class I and class II molecules that are in linkage disequilibrium with DQ2. However, it has been established that <50% of the genetic predisposition in CD and DH is due to specific HLA genes. However, genomic searches for non-HLA genes in patients with DH have to date been unsuccessful. Monozygotic twins, one with DH and the other with CD, have been reported, indicating that environmental as well as genetic factors play a role in the development of CD and/or its extraintestinal manifestation, DH[7].

Gluten-sensitive enteropathy (GSE)

In small bowel biopsies, more than 90% of DH patients have some degree of GSE. The bowel abnormality is caused by gliadin, the antigenic alcohol-soluble fraction of gluten. Gluten consists of a family of grain proteins found in: wheat, rye, barley, and hybrids of these grains (e.g. kamut, spelt, triticale). It is not found in rice, corn, sorghum, or most oats. The spectrum of intestinal involvement ranges from minimal infiltration of the lamina propria by lymphocytes (with normal villi), to minimal atrophy of the jejunum accompanied by intraepithelial lymphocytic infiltrates, to total villous atrophy of the small intestine. The enteropathy is often patchy and may require multiple small bowel samples for diagnosis. Symptomatic malabsorption occurs in ~20% of patients with DH.

The proposed pathogenesis of DH and CD is presented in Fig. 31.1. Following ingestion of gluten-containing grains (see above), one of the products of digestion is gliadin (see Fig. 31.1A). Once gliadin is absorbed via the lamina propria, glutamine residues within gliadin are deamidated by tissue transglutaminase (TG2) and covalent cross-links (isopeptidyl bonds) are formed between lysine residues in TG2 and glutamines in gliadin. Deamidation by TG2 is thought to be a critical step as it serves to optimize antigen presentation.

Deamidated gliadin peptides bind to the groove of the HLA-DQ2 molecule on dendritic antigen-presenting cells (see Fig. 31.1B), and the gliadin antigen is then presented to sensitized helper T cells in the context of HLA-DQ2 or DQ8 specificity. These helper T cells can stimulate B cells, with differentiated plasma cells producing IgA antibodies to multiple antigens, including gliadin, gliadin cross-linked to TG2, TG2, and epidermal transglutaminase (TG3). IgA anti-TG2 antibodies have become the serologic hallmark for CD.

In addition, stimulated natural killer (NK) lymphocytes cause crypt hyperplasia and villous atrophy. Elevated serum levels of interleukin (IL)-17 and IL-36 in patients with DH suggest a possible role for these cytokines in NK cell signaling and neutrophil activation[8]. The IL-31 pathway may also be involved in mediating the pruritus found in DH[9].

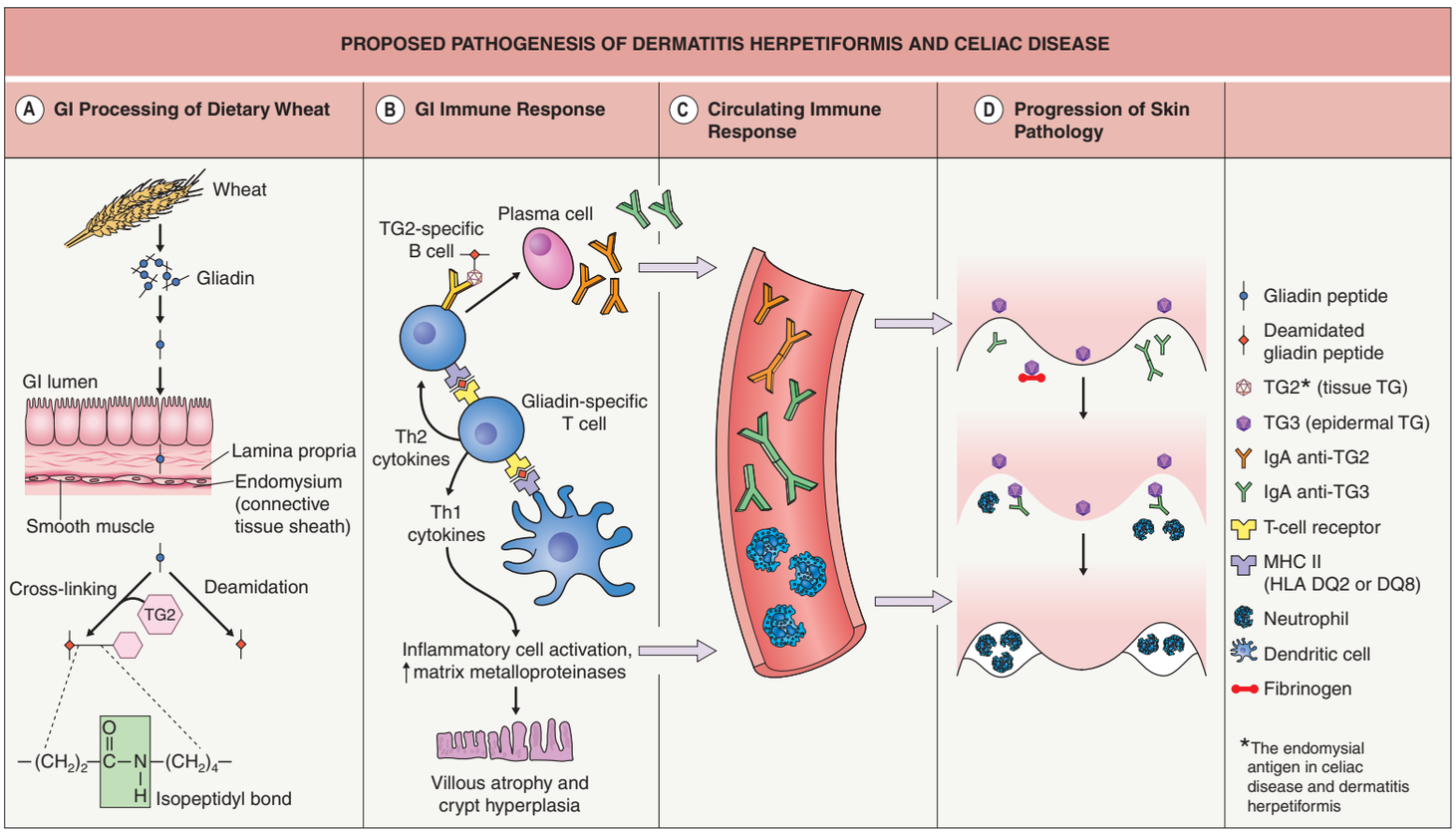

Fig. 31.1 Proposed pathogenesis of dermatitis herpetiformis and celiac disease. A Dietary wheat, barley, or rye is processed by digestive enzymes into antigenic gliadin peptides, which are transported intact across the mucosal epithelium. Within the lamina propria, tissue transglutaminase (TG2): (1) deamidates glutamine residues within gliadin peptides to glutamic acid; and (2) becomes covalently cross-linked to gliadin peptides via isopeptidyl bonds (formed between gliadin and TG2 lysine residues). **B** $CD4^+$ T cells in the lamina propria recognize deamidated gliadin peptides presented by HLA-DQ2 or -DQ8 molecules on antigen-presenting cells, resulting in the production of Th1 cytokines and matrix metalloproteinases that cause mucosal epithelial cell damage and tissue remodeling. In addition, TG2-specific B cells take up TG2–gliadin complexes and present gliadin peptides to gliadin-specific helper T cells, which stimulate the B cells to produce IgA anti-TG2. **C** Over time, IgA directed against TG3 (IgA anti-TG3) forms as a result of epitope spreading and both IgA anti-TG2 and IgA anti-TG3 circulate in the bloodstream. **D** When IgA anti-TG3 antibodies reach the dermis, they complex with TG3 antigens which have been produced by keratinocytes (epidermal TG) and then have diffused into the dermis. That is, IgA/TG3 immune complexes are formed *locally* within the papillary dermis. This leads to neutrophil chemotaxis (with formation of neutrophilic microabscesses), proteolytic cleavage of the lamina lucida, and subepidermal blister formation.

Downloaded for Anonymous User (n/a) at Egyptian Knowledge Bank from ClinicalKey.com by Elsevier on March 10, 2024. For personal use only. No other uses without permission. Copyright ©2024. Elsevier Inc. All rights reserved.

In the setting of continued exposure to gliadin, epitope spreading is thought to lead to development of IgA anti-TG3 antibodies in patients who already have IgA anti-TG2 antibodies. Patients with CD and DH have an immune response to TG2 within their intestinal mucosa, while those with DH have an additional response to TG3[10] (see Fig. 31.1B,D). Epitope spreading is a possible explanation for why DH tends to present at a later age than symptomatic CD (the latter often manifests in childhood) and why patients with CD alone tend to have more severe intestinal disease than patients with DH. Formation of IgA anti-TG3 antibodies is thought to require time and continued exposure to gluten and this would be more likely to occur in patients with less severe, relatively asymptomatic intestinal involvement. Findings in support of this theory include the presence of IgA anti-TG2 antibodies in most DH patients and a higher prevalence of IgA anti-TG3 antibodies in adults than in children with CD (i.e. developing later in the evolution of the disease). The declining incidence of DH, despite the rising incidence of CD, might further support this theory, with CD being diagnosed earlier before epitope spreading has the chance to occur[1].

The formation of IgA anti-TG3 antibodies also activates circulating neutrophils (see Fig. 31.1C). Deposition of these antibodies within the dermal papillae results in the infiltration of activated neutrophils from the circulation into the dermal papillae (see Fig. 31.1D). Degranulation of neutrophils releases proteases which disrupt the lamina lucida and produce a subepidermal blister.

Since both the skin disease and the intestinal disease resolve with dietary gluten restriction and recur with return to a regular diet, it is clear that the dietary protein gluten is central to the pathogenesis of the cutaneous eruption. In addition, it is the HLA class II antigen that acts as a gate through which gluten can reach the inflammatory cells and initiate the autoimmune process[11,12].

Circulating antibodies

The first serologic difference between DH and CD was described in 2002, with TG3 identified as the autoantigen in DH[13]. Additional studies have demonstrated that circulating IgA anti-TG3 antibodies are not only elevated in patients with DH, but can be assayed and may be helpful in monitoring response to a gluten-free diet[14,15]. TG3 was also found to co-localize with IgA in dermal papillae of DH patients and is enzymatically active in this site (see Fig. 31.5B)[13,16,17]. TG3 is expressed in many tissues of the body, including the epidermis. When IgA anti-TG3 antibodies reach the dermis, they complex with TG3 antigens which have been produced by keratinocytes (epidermal TG) and then have diffused into the dermis. In other words, IgA/TG3 immune complexes are formed *locally* within the papillary dermis (see Fig. 31.1D).

When goat anti-human TG3 antibodies (IgG) were passively transferred into SCID mice grafted with human skin, immune deposits were detected within the papillary dermis which reacted with rabbit anti-TG3 and DH sera. Transfer of sera from DH patients (who had high circulating levels of IgA anti-TG3 antibodies) led to similar granular IgA and TG3 dermal deposits[18]. In DH skin, IgA-bound deposits of TG3 are enzymatically active and therefore TG3 likely plays an important role in the covalent binding of IgA to connective tissue fibers. Enzymatically active TG3 also binds to soluble fibrinogen whose subsequent degradation may play a key pathogenic role[17]. In an animal model, evidence supported local formation of immune complexes in the papillary dermis, supplanting previous theories in which IgA complexes within DH skin were thought to represent deposits of circulating immune complexes.

Granular IgA deposition

Granular IgA deposition within dermal papillae is the hallmark of DH (see Fig. 31.5A). The deposits are composed of IgA1 antibodies directed against TG3. Circulating IgA antibodies to TG2 (an endomysial antigen) have been identified by indirect immunofluorescence (IIF) microscopy using a monkey esophagus substrate, and the presence of these antibodies correlates with the degree of GSE. IgA anti-TG3 antibodies, but not IgA anti-TG2 antibodies, are responsible for the IgA deposition in DH skin.

Iodide

Ingestion of iodide can lead to worsening of DH and topical application of iodide onto the normal skin of DH patients produces lesions that are histologically identical to spontaneous lesions. Even in normal subjects, topical iodides may produce follicular neutrophilic pustules. When potassium iodide is added to DH skin *in vitro*, the enzymatic activity of TG3 that is complexed to IgA dramatically increases[19]. It is therefore possible that the clinical worsening of DH after iodide application or ingestion is due to an iodide-induced increase in TG3 activity. In patients with refractory DH, a search for covert iodide ingestion should be undertaken as iodide can be found in medications, dietary supplements, and foods (e.g. eggs), in addition to radiographic contrast media[19a].

Associated Disorders and Malignancies

A strong association exists between DH and thyroid disease, particularly Hashimoto thyroiditis. In one study, the presence of some type of thyroid abnormality was found in 26 of 50 patients with DH[20]. Although the pathogenetic relationship between DH and thyroid disease is unknown, it may represent a coexistence of autoimmune disease[20]. The incidence of enteropathy-associated T cell lymphoma is also increased in patients with DH and warrants increased surveillance. Of note, adhering to a gluten-free diet protects against developing lymphoma, in particular after the patient has adhered to a gluten-free diet for five years. This further supports advising patients with DH to adhere to a strict gluten-free diet *ad infinitum*. Other autoimmune disorders reported to be associated with DH and CD are listed in Table 31.2.

Clinical Features

DH has a symmetric distribution and favors the elbows, knees, extensor forearms, back, and buttocks (Fig. 31.2 & 31.3). The primary lesions are pleomorphic, with urticarial plaques, papules, and vesicles. Grouped or "herpetiform" papulovesicles with an erythematous base are characteristic of this autoimmune disorder. Intense pruritus leads to secondary excoriation and crusting. Even if only hemorrhagic crusts or secondary changes from scratching are present, the diagnosis should be suspected on the basis of the distribution pattern. Less common presentations are isolated facial or scalp involvement, exclusively macular lesions, and hemorrhagic acral macules (usually palmoplantar; see Fig. 31.3C).

Pathology

For routine histology, it is optimal to capture a small, intact vesicle. If this is not available, an area of erythema should be biopsied. Areas of erythema will show dermal papillary edema and neutrophil infiltration associated with a superficial perivascular lymphocytic infiltrate. Dermal papillae filled with neutrophils, with relative sparing of the lowermost tips of the intervening rete ridges, is a characteristic finding. When an intact vesicle is biopsied, a subepidermal blister containing predominantly neutrophils is usually seen (Fig. 31.4). Sometimes only a lymphohistiocytic infiltrate or spongiosis is seen, emphasizing the important role of direct immunofluorescence (DIF) microscopy[15,21]. Also, as with other autoimmune bullous disorders, the presence of typical histologic features depends on the site and quality of the biopsy.

AUTOIMMUNE DISORDERS ASSOCIATED WITH DERMATITIS HERPETIFORMIS	
Common	
• Autoimmune thyroid disease (Hashimoto thyroiditis) • Insulin-dependent diabetes mellitus	
Uncommon	
• Pernicious anemia	
Rare	
• Addison disease • Autoimmune chronic active hepatitis • Alopecia areata • Myasthenia gravis • Sarcoidosis	• Systemic sclerosis (scleroderma) • Sjögren syndrome • Systemic lupus erythematosus • Vitiligo

Table 31.2 Autoimmune disorders associated with dermatitis herpetiformis.

Downloaded for Anonymous User (n/a) at Egyptian Knowledge Bank from ClinicalKey.com by Elsevier on March 10, 2024. For personal use only. No other uses without permission. Copyright ©2024. Elsevier Inc. All rights reserved.

Fig. 31.2 Dermatitis herpetiformis. A Pink papulovesicles, erosions, and hemorrhagic crusts on the elbow. **B** Multiple urticarial pink papules on the knee, in addition to a few erosions and small subtle intact vesicles (arrows and half-circles). **C** Pink plaques on the knee composed of grouped papules and papulovesicles, admixed with tiny hemorrhagic crusts. **D** Crusted papules as well as an intact vesicle on the elbow. *C, Courtesy Thomas Horn, MD.*

IgA Deposits

In patients with DH, dermal IgA deposits are not uniformly distributed throughout the skin. Notably, IgA deposits are present in greater amounts near active lesions. The optimal biopsy site for DIF microscopy is normal-appearing skin immediately adjacent to a lesion (see Fig. 29.12). A false-negative DIF can occur if lesional skin is biopsied, since the inflammatory infiltrate can destroy the epitopes on IgA[22]. A definitive diagnosis of DH depends upon the demonstration of dermal IgA deposits by DIF microscopy. Granular IgA deposits localized to the dermal papillae are found in 85% of cases of DH (Fig. 31.5), while continuous granular deposition of IgA along the basement membrane occurs in 5% to 10% of cases. A fibrillar pattern of IgA deposition occurs rarely although it is more commonly observed in Japanese patients[23]. Because DH represents a lifetime diagnosis with systemic and therapeutic implications, definitive immunopathologic confirmation is essential.

Although granular deposits of IgA in the skin along with serum IgA anti-TG3 antibodies is considered characteristic of DH, a recent study found that a subset of newly diagnosed CD patients without skin disease could have cutaneous IgA deposits and circulating IgA anti-TG3 antibodies[24]. It is possible that this subset of CD patients may go on to develop DH.

Laboratory evaluation

Anti-endomysial IgA antibodies are very specific for the GSE present in CD and DH. Their levels indicate the severity of GSE and reflect the degree of compliance with dietary gluten restriction. IgA anti-endomysial antibodies are found in ~80% of patients with DH and >95% of patients with active CD at the time of diagnosis. The endomysium is the connective tissue covering the smooth muscle layers of the esophagus, stomach, and small intestine (see Fig. 31.1A) and TG2 has been identified as the endomysial antigen.

Anti-TG2 and -TG3 antibodies play a key role in the pathogenesis of CD and DH (see above). The normal physiologic function of transglutaminase is to repair injured tissue by cross-linking extracellular matrix proteins in order to protect surrounding tissue from further damage. Transglutaminase facilitates the linkage of the carboxamide group of the amino acid glutamine, found in gliadin, to an ε-amino group of a lysine residue in transglutaminase located in the intestinal tract (see Fig. 31.1A). The glutamine in gliadin is especially vulnerable to cross-linkage with transglutaminase, and this linkage is perceived as a foreign antigen by the host immune system. As antibodies to transglutaminase are produced, the normal function of transglutaminase in repairing the damaged intestinal mucosa is impaired.

Downloaded for Anonymous User (n/a) at Egyptian Knowledge Bank from ClinicalKey.com by Elsevier on March 10, 2024. For personal use only. No other uses without permission. Copyright ©2024. Elsevier Inc. All rights reserved.

Fig. 31.3 Dermatitis herpetiformis. A Grouped pink papulovesicles on the upper back, neck, and scalp in a child. **B** Pruritic pink papules on the buttocks, some of which have central hemorrhagic crusts and are grouped. **C** Multiple hemorrhagic macules on the fingertips. *B, Courtesy Louis A. Fragola, Jr, MD; C, Courtesy Jeffrey Callen, MD.*

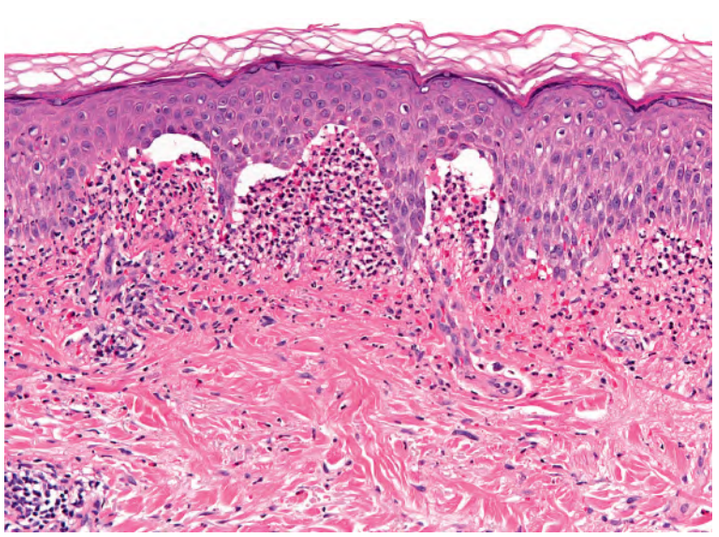

Fig. 31.4 Dermatitis herpetiformis – histopathologic features. Subepidermal clefts beneath which are collections of neutrophils within dermal papillae. Scattered eosinophils are also present. *Courtesy Lorenzo Cerroni, MD.*

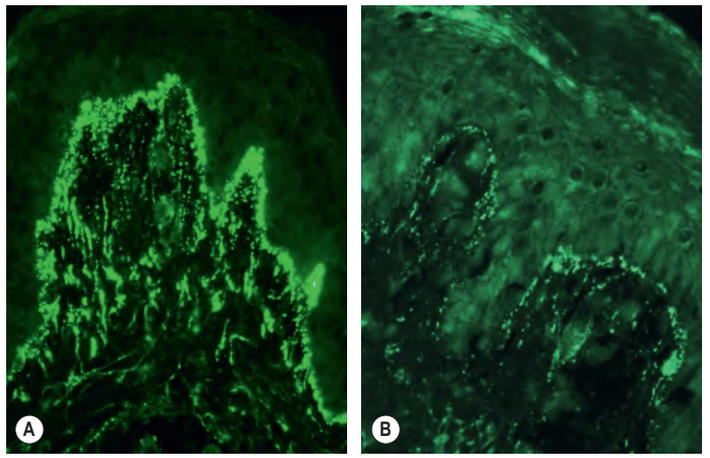

Fig. 31.5 Dermatitis herpetiformis – direct immunofluorescence. A Granular IgA deposition along the dermal–epidermal junction of normal-appearing skin adjacent to a lesion. **B** Granular deposition of epidermal transglutaminase (TG3) within the dermal papillae, which co-localizes with the IgA. *A, Courtesy Kristin Leiferman, MD.*

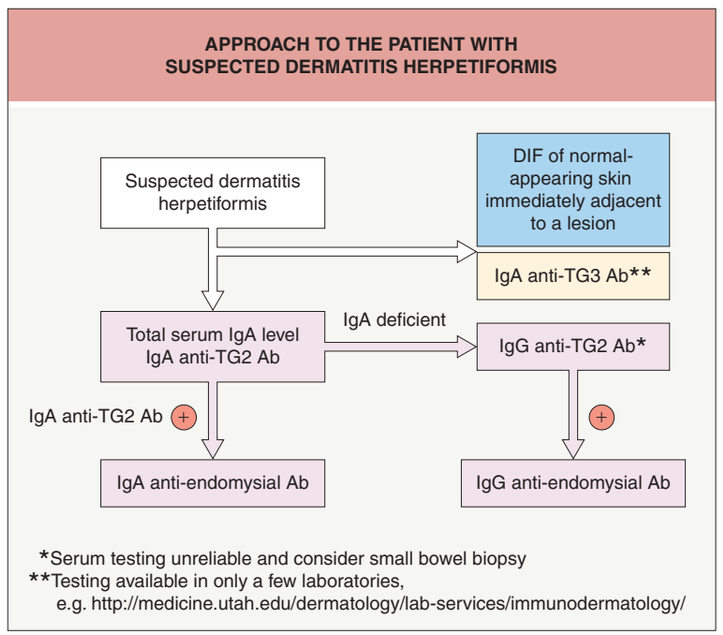

Fig. 31.6 Approach to the patient with suspected dermatitis herpetiformis. IgA anti-TG2 and anti-endomysial antibodies can be monitored over time to assess compliance with a gluten-free diet. Because the anti-endomysial antibody assay is based upon analysis of indirect immunofluorescence, it is more expensive than the IgA anti-TG2 antibody assay; thus, the recommendation that the latter assay be performed first. Anti-deamidated gliadin peptide IgG testing may have utility for individuals with IgA deficiency or weakly positive anti-TG2 IgA. Ab, antibody; DIF, direct immunofluorescence; TG, transglutaminase.

An approach to the laboratory evaluation of a patient with suspected DH is outlined in Fig. 31.6.

Differential Diagnosis

The differential diagnosis includes arthropod assault, scabies, and urticarial vasculitis, as well as erythema multiforme, bullous lupus erythematosus, linear IgA bullous dermatosis (LABD), and bullous pemphigoid. Table 31.3 outlines the clinical and histologic features that help differentiate DH from LABD and bullous pemphigoid. Erythema multiforme is characterized by target lesions that are often acral in distribution and show vacuolar degeneration and focal epidermal necrosis histologically as well as a lack of IgA deposition at the basement membrane zone (BMZ; see Ch. 20).

Downloaded for Anonymous User (n/a) at Egyptian Knowledge Bank from ClinicalKey.com by Elsevier on March 10, 2024. For personal use only. No other uses without permission. Copyright ©2024. Elsevier Inc. All rights reserved.

CHARACTERISTICS THAT DIFFERENTIATE DH, LABD, AND BP			
	DH	**LABD**	**BP**
Cutaneous lesion	Grouped papules and small vesicles, often excoriated	Small vesicles and/or large bullae	Large tense bullae
Distribution pattern	Extensor surfaces, symmetrical	Similar to DH or BP; may involve mucosae	Trunk, extremities, occasionally mucosae
Routine histology	Subepidermal bullae with neutrophilic infiltrate	Subepidermal bullae with neutrophilic infiltrate (sometimes eosinophils predominate)	Subepidermal bullae with eosinophilic infiltrate
Direct IF	Granular IgA in dermal papillae	Linear IgA at BMZ, possibly also IgG	Linear IgG and C3 at BMZ
Site to biopsy for direct IF	Adjacent normal-appearing skin	Perilesional	Perilesional
Routine indirect IF	Negative	Linear IgA at BMZ (70%)	Linear IgG at BMZ (70%)
Enteropathy	>90%	Rare	None
HLA-DQ2	>90%	30%	Normal (20%)
Dapsone responsiveness	Excellent	Good, may also require systemic corticosteroids	Minimal to moderate

Table 31.3 Characteristics that differentiate dermatitis herpetiformis (DH), linear IgA bullous dermatosis (LABD), and bullous pemphigoid (BP). BMZ, basement membrane zone; IF, immunofluorescence.

SIDE EFFECTS OF DAPSONE		
Red blood cell toxicity	• Hemolytic anemia • Methemoglobinemia*	
White blood cell toxicity	• Leukopenia • Agranulocytosis	
Dapsone hypersensitivity syndrome	• Fever, fatigue, anorexia, hepatitis, lymphadenopathy	
Cutaneous reactions	• Morbilliform eruption • Urticaria • Fixed drug eruption • Erythema nodosum • Exfoliative dermatitis	• SJS/TEN • Phototoxicity • Drug-induced cutaneous lupus erythematosus
Gastrointestinal manifestations†	• Anorexia, nausea • Hepatitis • Cholestatic jaundice • Severe hypoalbuminemia	
Neurologic associations†	• Headache, dizziness • Peripheral neuropathy • Blurred vision, tinnitus • Insomnia • Psychosis	
Miscellaneous	• Fever • Nephrotic syndrome	

*Patients should be warned that arterial desaturation may be noted by pulse oximetry, even with relatively low levels of methemoglobinemia.
†In decreasing order of frequency.

Table 31.4 Side effects of dapsone. SJS, Stevens–Johnson syndrome; TEN, toxic epidermal necrolysis.

Bullous lupus erythematosus presents with urticarial papules and vesicles on an erythematous base and a histologic picture similar to LABD and DH. However, the patients have clinical and serologic findings of systemic lupus erythematosus. DIF reveals multiple immunoglobulins (including IgA) in a granular or broad linear pattern along the BMZ, whereas in LABD there is a fine linear IgA deposition.

Crusted papules are also seen on the elbows and knees in patients with granulomatosis with polyangiitis and eosinophilic granulomatosis with polyangiitis, but histologic features of vasculitis are observed.

Treatment

The treatment of DH includes dapsone and a gluten-free diet, with the pruritus of DH relieved within 48–72 hours after instituting dapsone (4′,4′ diamino-diphenyl sulfone). Lesions abruptly recur within 24–48 hours of therapy discontinuation. However, dapsone has no effect on the intestinal pathology.

Dapsone is begun after screening for glucose-6-phosphate dehydrogenase (G6PD) deficiency, with initial dosages of 25–50 mg in adults and 0.5 mg/kg in children. Initiation of therapy with higher doses may precipitate severe hemolysis and cardiac decompensation in susceptible individuals. The average maintenance dose in adults on a normal diet is 50–100 mg daily. The half-life ranges from 12 to 32 hours, so divided doses are seldom of benefit. The daily dose can be regulated on a weekly basis to optimize control. One to two new lesions per week should be expected on the optimal dose. Higher doses increase toxicity with little benefit.

Outbreaks of facial and scalp lesions while on otherwise adequate treatment can occur, but are not common. Facial disease may prove refractory to dapsone therapy. Breaking the vesicles followed by application of a potent corticosteroid gel may be helpful.

Although there are many side effects of dapsone (Table 31.4; see Ch. 130), the drug is well tolerated for years in more than 90% of patients. Hemolysis occurs in virtually every patient on dapsone therapy, since sulfones produce an oxidant stress on aging red blood cells. In patients with G6PD deficiency, dapsone may produce severe hemolysis. Although most patients have evidence of drug-induced hemolysis, a compensated *hemolytic anemia* develops. Drug-induced hemolysis can be confirmed and followed by a reticulocyte count, which should show increased erythropoiesis. Of note, dapsone is secreted in breast milk and may cause hemolytic anemia in breastfed infants. In the setting of a persistent severe anemia, a search for contributing causes, such as iron, vitamin B_{12} or folate deficiencies or hereditary spherocytosis, should be pursued.

Methemoglobin is present in the blood of most patients taking 100 mg or more of dapsone daily. Although the amount of methemoglobin usually does not exceed 5%, there are patients who have maintained levels between 10% and 15%. Methemoglobinemia in the absence of cardiopulmonary symptoms does not require alteration of dapsone dose. Patients should be warned that arterial desaturation may be noted by pulse oximetry, even with relatively low levels of methemoglobinemia.

Fatal *agranulocytosis* has developed in patients with DH treated with dapsone. This drug-induced agranulocytosis usually occurs after 2–12 weeks of continuous dapsone treatment. Re-administration of dapsone then causes leukopenia within hours. A simple measure is to warn the patient to discontinue the drug and report immediately if fever, a sore throat, or other signs of infection develop.

Dapsone hypersensitivity syndrome (see Ch. 21) is a rare, but potentially severe, reaction, characterized by fever, a cutaneous eruption, and internal organ involvement. It is usually seen 2–7 weeks after initiation of therapy. The cutaneous manifestations vary from a morbilliform eruption to exfoliative dermatitis, while the systemic manifestations include fever, pruritus, lymphadenopathy, hepatitis, an elevated ESR, leukocytosis, and, rarely, eosinophilia. Among patients with leprosy, HLA-B*13:01 has been associated with the development of the dapsone hypersensitivity syndrome. Reported population frequencies of HLA-B*13:01 are 2%–20% (Chinese), 1.5% (Japanese), 1%–12% (Indians), and 2%–4% (Southeast Asians); this allele is largely absent in Europeans and Africans[25]. Patients should be educated about this syndrome and instructed to discontinue therapy and notify their medical provider if any signs or symptoms of the dapsone hypersensitivity syndrome develop.

Peripheral neuropathy induced by dapsone may occur within the first few weeks of therapy. The neuropathy was initially reported as a pure motor neuropathy (involving primarily distal extremity muscles);

Downloaded for Anonymous User (n/a) at Egyptian Knowledge Bank from ClinicalKey.com by Elsevier on March 10, 2024. For personal use only. No other uses without permission. Copyright ©2024. Elsevier Inc. All rights reserved.

however, pure motor, pure sensory, and combined motor and sensory neuropathies have subsequently been reported. Relatively high daily doses of dapsone (200–500 mg) have been implicated.

If patients are intolerant to dapsone, therapy with **sulfapyridine** can be considered. The initial dose of sulfapyridine is usually 500 mg three times daily and it can be safely increased to 2 g three times a day; however, some patients may not respond to sulfapyridine at any dose. Adequate fluid intake and alkalinization of the urine minimizes the risk of nephrolithiasis. Because sulfapyridine is currently not commercially available in the US, sulfasalazine may be used as a second alternative. Sulfasalazine is metabolized to sulfapyridine and 5-aminosalicylate by intestinal bacteria, making dosing less predictable. In adults, a standard starting dose is 500 mg four times daily.

Dapsone monitoring includes a baseline complete blood count (CBC) and liver function tests, then weekly CBCs for the first month, twice monthly CBCs for the second month, then monthly CBCs for the next 4 months, and semiannual CBCs thereafter while the patient remains on therapy. Liver function tests should be repeated at 6 months and annually thereafter. Some clinicians measure baseline G6PD activity in all patients, while others focus on those of African, Asian, or southern Mediterranean ancestry. Sulfapyridine rarely produces hemolytic anemia, but the potential for agranulocytosis does exist. Consequently, similar monitoring is recommended for chronic sulfapyridine or sulfasalazine therapy.

Patients can also be treated with a **gluten-free diet** (which includes corn, rice, and most oats). Because several months on a gluten-free diet is typically needed for a response, concurrent suppression of symptoms with dapsone is usually necessary. Most patients with granular IgA deposits respond to a strict gluten-free diet such that they can either decrease or eliminate their need for dapsone. With a prolonged gluten-free diet, IgA in the skin decreases and eventually disappears, but with the reintroduction of gluten, IgA deposits and skin disease return in the vast majority of patients. Minor fluctuations in disease severity are most likely related to oral gluten intake. The gluten-free diet is inconvenient and unacceptable to some patients.

Patient Support

The Gluten Intolerance Group and the Celiac Disease Foundation (www.celiac.org) offer information on foods and additives that should be avoided. The former patient support group has a *Quick Start Gluten-Free Diet Guide* that may be useful for patients. Their website is www.gluten.org.

LINEAR IgA BULLOUS DERMATOSIS

Synonyms: Adults: ▪ Linear IgA dermatosis (LAD) ▪ Linear IgA disease of adults ▪ Linear IgA disease ▪ Linear IgA dermatitis herpetiformis ▪ Linear dermatitis herpetiformis ▪ Adult linear IgA disease ▪ IgA bullous pemphigoid ▪ Pemphigoid linear IgA

Children: ▪ Chronic bullous disease of childhood ▪ Benign chronic bullous dermatosis of childhood ▪ Childhood linear IgA dermatitis herpetiformis ▪ Linear IgA disease of childhood

Introduction

LABD is an immune-mediated, subepidermal, vesiculobullous eruption that occurs in both adults and children. It has been defined on the basis of a unique immunopathology consisting of linear deposition of IgA along the cutaneous BMZ. In adults, the clinical findings associated with this immunopathologic pattern may resemble those of DH or bullous pemphigoid (BP) (see Table 31.3), but in children, the cutaneous features may be clinically unique.

The childhood form is frequently termed "chronic bullous disease of childhood" (CBDC). It is a subepidermal vesiculobullous disease that was initially described on the basis of its clinical findings – annular erythema and blisters (often referred to as a "crown of jewels"), which developed predominantly in flexural areas, particularly the lower trunk, thighs and groin, in preschool children (Fig. 31.7). However, it is invariably characterized by the linear deposition of IgA along the BMZ (Fig. 31.8) as well as circulating antibodies against the same BMZ antigens described in the adult form[26].

Fig. 31.7 Linear IgA bullous dermatosis. Characteristic findings in this child include the annular array of bullae (inset) and involvement of the genital region. There are also tense bullae arising on normal-appearing skin with either clear or hemorrhagic fluid and annular bullae with central crusting. *Courtesy Antonio Torello, MD.*

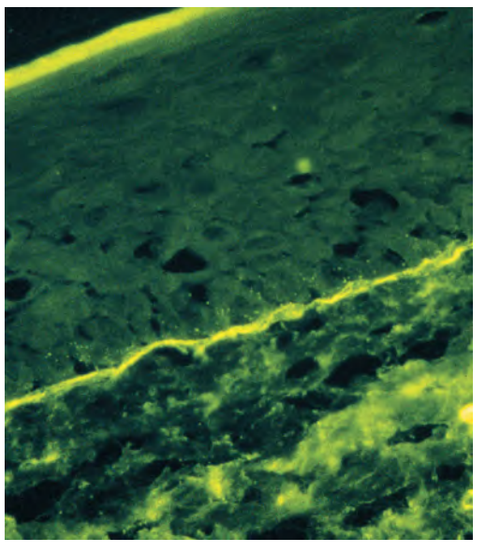

Fig. 31.8 Linear IgA bullous dermatosis – direct immunofluorescence. A linear pattern of IgA deposition is present within perilesional skin.

There are two distinct types of LABD based upon the site of IgA deposition as determined by immunoelectron microscopy: a lamina lucida type (majority) and a sublamina densa type. In adults, LABD is frequently drug-induced.

History

In 1969, it was noted that patients with vesiculobullous lesions and the histologic findings of DH could have linear rather than granular deposits

Downloaded for Anonymous User (n/a) at Egyptian Knowledge Bank from ClinicalKey.com by Elsevier on March 10, 2024. For personal use only. No other uses without permission. Copyright ©2024. Elsevier Inc. All rights reserved.

of IgA along the epidermal BMZ[27]. In 1975, Chorzelski and Jablonska[28] first suggested the term LABD and suggested that it was a separate entity based on its immunopathologic findings. Since then, there has been general agreement that LABD is a distinct disease entity from DH[29,30]. Nowadays, the term linear IgA disease (LAD) is often used as synonymous with LABD and perhaps is a preferred term, especially when there is mucosal involvement.

In 1970, Jordon et al.[31] first proposed the name "benign chronic bullous dermatosis of childhood". Subsequent investigators, using antisera specific for IgA, identified the characteristic linear IgA deposition along the epidermal BMZ in children with CBDC[32]. On a molecular basis, CBDC is the same disease as LABD in that the circulating IgA antibody found in the serum of patients with CBDC binds to the same 97 kDa proteolytic fragment of BP180 antigen described in adults with LABD[26].

Epidemiology

The annual incidence of LABD varies globally, ranging from 0.5 to 2.3 cases per million per year[33]. Incidence in the US has not been reported, but we have estimated the prevalence of LABD in Utah to be 0.6 per 100 000 adults. In adults, the average age of onset of LABD is over 60 years of age[33,34]. There appears to be a slight female preponderance, although this has not been observed in all series[33]. Childhood LABD occurs at a mean age of 4.5 years[34].

Pathogenesis

Both BP and the lamina lucida type of LABD have lamina lucida deposition of immunoglobulin and are associated with BMZ vesiculation. However, the antigenic specificity differs. In BP, the pathogenic IgG antibodies bind the MCW-1 region of the NC16 domain of BP antigen 2 (BPAG2; BP180), whereas the epitopes that have stimulated an IgA response in LABD are toward the carboxy terminus of the same molecule (Fig. 31.9)[35]. In adult and childhood LABD patients, this IgA antibody was initially found, on immunoblot, to react against a 97 kDa antigen in an epidermal extract[36]. Subsequently, there was definitive characterization of the antigenically active fragments of the physiologically cleaved BP180 ectodomain[37]. Sera from LABD patients preferentially react with two fragments that contain neoepitopes but not with intact BP180. These two fragments are LAD-1 (120 kD) and LABD97 (97 kD; see Fig. 31.9)[37]. Why BP antibodies should react predominantly with antigens near the transmembrane portion of BPAG2 and LABD antibodies react with cleaved epitopes within the collagenous domain is unclear.

IgA class antibodies from patients with the sublamina densa type of LABD have been reported to bind to type VII collagen within anchoring fibrils[38,39].

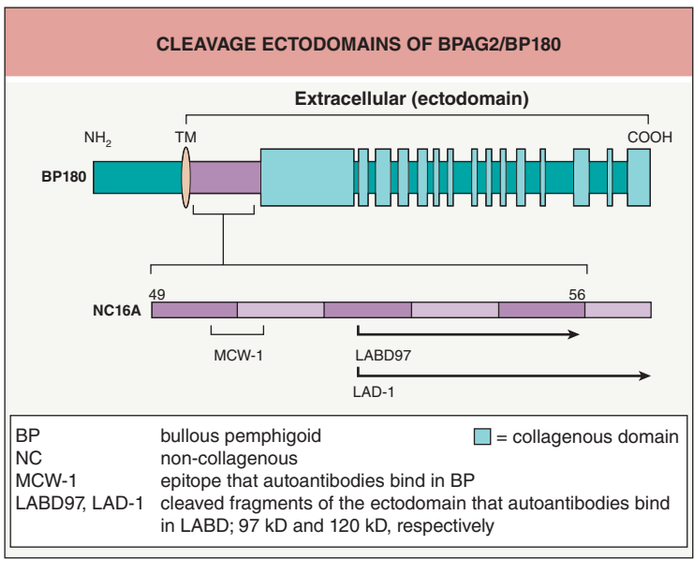

Fig. 31.9 Cleavage ectodomains of BPAG2/BP180. BP, bullous pemphigoid; COOH, carboxy terminus; LABD, linear IgA bullous dermatosis; NH_2, amino terminus; TM, transmembrane region.

There have been reports in the literature of the association of LABD with various disorders such as gastrointestinal diseases, autoimmune diseases, malignancies, and infections (see below). The significance of these associations is yet to be determined, but they may play a role in the initial stimulation of the IgA mucosal immune system.

The incidence of gluten-sensitive enteropathy in LABD has been reported in the literature to range from 0 to 24%[30,32,40]. In one case series, two of six patients with LABD had gluten-sensitive enteropathy, and two of six patients' skin lesions improved on a gluten-free diet; however, none of the patients completely cleared[40]. In contrast, a second series found no histologic evidence of gluten-sensitive enteropathy in the six patients they studied[30]. LABD clearly has a much lower prevalence of small bowel histologic abnormalities than does DH. Ulcerative colitis, Crohn disease, and gastric hypochlorhydria have also been described in association with LABD[29,41]. LABD associated with ulcerative colitis was reported to remit after colectomy[42].

Data on the association of autoimmune diseases with LABD are not sufficient to allow statistical analysis of prevalence. However, there are reports in the literature of the association of systemic lupus erythematosus and dermatomyositis with LABD, as well as thyrotoxicosis, autoimmune hemolytic anemia, rheumatoid arthritis, and glomerulonephritis[43,44].

An association between LABD and malignancy has also been described. Tumors that have been reported in patients with LABD include: B cell lymphoma, chronic lymphocytic leukemia, and carcinoma of the bladder, thyroid, colon and esophagus; single case reports of plasmacytoma, hydatidiform mole, renal cell carcinoma, and ocular melanoma have also been described[33,45–48]. In addition, LABD has been reported to be associated with several infections, including varicella zoster virus, antibiotic-treated tetanus, and upper respiratory infections. It has been postulated that the infectious agent may have triggered an immune response[49,50]. Lastly, there are reports of new-onset LABD developing after SARS-CoV-2 vaccination, but whether this represents a true association remains speculative.

There are multiple reports of drug-induced LABD; the drugs associated with LABD are listed in Table 31.5, with vancomycin being the most common inducer (Fig. 31.10)[51,52]. While IIF studies are generally

DRUG-INDUCED LINEAR IgA BULLOUS DERMATOSIS	
Common	
• Vancomycin*	
Less common	
• Penicillins	
• Cephalosporins	
• Captopril > other ACE inhibitors	
• NSAIDs: diclofenac, naproxen, oxaprozin, piroxicam	
Uncommon	
• Phenytoin	
• Sulfonamide antibiotics: sulfamethoxazole, sulfisoxazole	
Rare	
• Acetaminophen	• Infliximab
• Allopurinol	• Influenza vaccination
• Amiodarone	• Interferon-α and interferon-γ
• Amlodipine	• Interleukin-2
• Angiotensin receptor blockers: candesartan, eprosartan	• Lithium carbonate
• Atorvastatin	• Metronidazole
• Buprenorphine	• Minocycline
• Carbamazepine	• Moxifloxacin
• Cyclosporine	• PUVA
• Enoxaparin	• Rifampin
• Furosemide	• Somatostatin
• Gemcitabine	• Tea tree oil
• Glibenclamide	• Ustekinumab
• Glyburide	• Verapamil
• Granulocyte colony-stimulating factor	• Vigabatrin
*Unusual variants include toxic epidermal necrolysis-like and morbilliform.	

Table 31.5 Drug-induced linear IgA bullous dermatosis. ACE, angiotensin-converting enzyme; NSAIDs, nonsteroidal anti-inflammatory drugs.

Downloaded for Anonymous User (n/a) at Egyptian Knowledge Bank from ClinicalKey.com by Elsevier on March 10, 2024. For personal use only. No other uses without permission. Copyright ©2024. Elsevier Inc. All rights reserved.

Fig. 31.10 Drug-induced linear IgA bullous dermatosis. Annular vesicopustules and central crusting are seen in this patient receiving vancomycin.

Fig. 31.11 Linear IgA bullous dermatosis. Vesicles and bullae arising within normal-appearing skin as well as scattered annular lesions. The former can also be seen in bullous pemphigoid. *Courtesy Jeffrey P. Callen, MD.*

negative in drug-induced LABD, addition of vancomycin to patients' sera can result in a positive IIF assay, with reactivity against the NC1 domain of type VII collagen. These novel findings suggest that vancomycin either mediates or enhances IgA autoreactivity to type VII collagen[53]. Drug-induced LABD usually remits within 2–6 weeks of cessation of the drug, although it can persist for months[52].

Clinical Features

Clinical manifestations of LABD are variable and patients can present with findings suggestive of DH as well as subepidermal tense bullae that are often indistinguishable from BP (Fig. 31.11). However, the vesiculobullous lesions often appear in a herpetiform arrangement on

Fig. 31.12 Linear IgA bullous dermatosis. Annular and herpetiform vesicles arising on an inflammatory base. Annular pink plaques are also present. *Courtesy Jeffrey P. Callen, MD.*

Fig. 31.13 Linear IgA bullous dermatosis. Striking annular vesiculobullous lesions on the thigh with central erosions and crusting. A figurate outline is seen in the area of coalescence.

erythematous and/or normal-appearing skin (Fig. 31.12). Some patients present with expanding annular plaques (Fig. 31.13), while others have lesions that are scattered and asymmetric[29]. An isomorphic response, including lesions appearing at previous sites of adhesive tape, has been reported.

LABD may present as a variant of mucous membrane pemphigoid, with oral, nasal, pharyngeal, and esophageal lesions. Involvement of the tracheobronchial mucosa was reported in a severe case[54]. The ocular form of LABD is clinically indistinguishable from ocular mucous membrane pemphigoid[55].

LABD secondary to drugs, in particular vancomycin, may have a toxic epidermal necrolysis (TEN)-like or morbilliform presentation.

Pathology

LABD is a subepidermal vesicular dermatosis in which neutrophils predominate. In early urticarial papules or plaques, neutrophils are aligned along the BMZ, accompanied by vacuolar change and sometimes

Downloaded for Anonymous User (n/a) at Egyptian Knowledge Bank from ClinicalKey.com by Elsevier on March 10, 2024. For personal use only. No other uses without permission. Copyright ©2024. Elsevier Inc. All rights reserved.

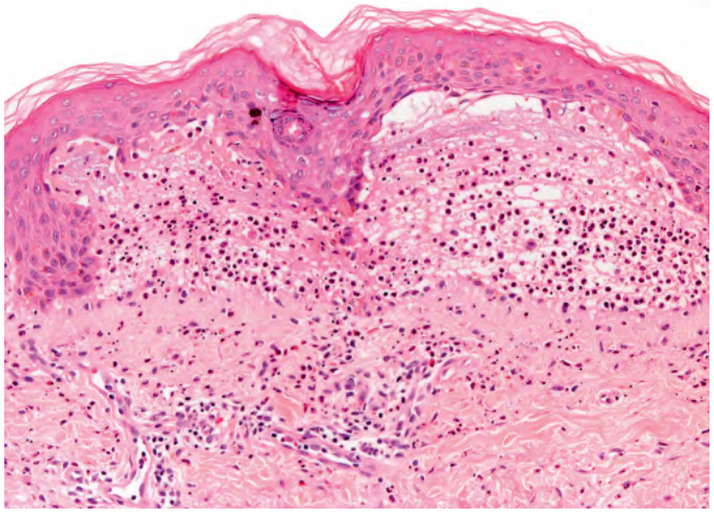

Fig. 31.14 Linear IgA bullous dermatosis – histopathologic features. Subepidermal blister filled with neutrophils. Neutrophils and a few eosinophils are also present within the underlying dermis. *Courtesy Lorenzo Cerroni, MD.*

by neutrophilic microabscesses in dermal papillae. These papillary dermal collections, if numerous enough, can resemble the picture seen in DH[29]. In fully developed lesions, there are subepidermal bullae in which neutrophils are present in the underlying dermis, either alone or with eosinophils (Fig. 31.14). Eosinophils can become more numerous over time, particularly in adults, thus mimicking the histopathologic picture of bullous pemphigoid. Although in most cases distinguishing between DH and LABD is impossible by light microscopy, a linear distribution of neutrophils along the BMZ and neutrophils at the very tips of dermal papillae favor LABD[56]. However, the latter cannot be considered a specific finding.

LABD can be subdivided on the basis of immunoelectron microscopy findings, with most patients having IgA deposits within the lamina lucida[30,57]. Less commonly, there is deposition of IgA in the sublamina densa, associated with anchoring fibrils[30]. In a few cases, deposits of IgA have been observed in both sites[58]. In one report, the deposition of IgA was initially in the lamina lucida, but later had a combined pattern[58].

Galactose-deficient IgA1 (Gd-IgA1) is implicated in the pathogenesis of IgA nephropathy and deposits of Gd-IgA1 have been detected in systemic and skin-limited forms of IgA vasculitis[59]. However, the role of Gd-IgA1 in DH and LABD remains unknown. A single case report has suggested the passive transfer of pathogenic IgA autoantibodies to a newborn from an asymptomatic mother via breast milk[59a].

Differential Diagnosis

LABD can be difficult to diagnose clinically, especially in adults, and is often confused with DH and BP. By definition, LABD is separated from DH and BP on the basis of findings by DIF (see Table 31.3). Linear IgA deposition along the BMZ in perilesional skin is characteristic of LABD (see Fig. 31.8), in contrast to either DH, which shows granular deposition of IgA in dermal papillary tips or in a continuous pattern along the basement membrane[28–30], or BP, which shows linear deposition of IgG along the epidermal BMZ. The classification of cases demonstrating both IgG and IgA along the BMZ is problematic. Some authorities include only those patients with IgA as the sole BMZ immunoglobulin under the term LABD and categorize all others as BP. Others categorize patients with both IgG and IgA along the BMZ based on the predominant immunoglobulin by DIF. Perhaps the most important point is that patients with IgA along the BMZ, alone or in combination with IgG, are more likely to respond to dapsone therapy. Distinguishing the sublamina densa form of LABD from epidermolysis bullosa acquisita is also made on the basis of the class of immunoreactant and classification can be problematic.

Circulating anti-BMZ antibodies of the IgA class can be demonstrated in 60%–70% of LABD sera. In contrast, patients with DH have not been shown to have circulating antibodies that bind to skin, and 60%–70% of patients with BP demonstrate circulating IgG class antibodies (see Table 31.3)[28]. Circulating IgA class anti-BMZ antibodies from the lamina lucida type of LABD have been shown to adhere to the epidermal side (roof) of salt-split skin, while patients with sublamina densa binding of IgA on direct immunoelectron microscopy have serum antibodies which bind to the dermal side of salt-split skin. Patients with both IgA and IgG at the BMZ demonstrate binding to the epidermal side of salt-split skin[60]. Whether or not such antibody titers correlate with disease activity has not yet been established.

For the morbilliform or TEN-like presentation of LABD due to drugs, in particular vancomycin, routine microscopy plus DIF aids in the diagnosis.

Treatment

The majority of patients with LABD respond to oral dapsone, sulfapyridine or sulfasalazine. These medications have been reviewed in detail in the section on the treatment of DH. Most patients with LABD have a clinical response within 48–72 hours. In occasional patients, it may be necessary to add oral prednisone in doses up to 40 mg daily to achieve complete control of the disease. However, the majority of our patients have been controlled by dapsone alone. It is our observation that patients in whom both IgG and IgA deposits are present in the BMZ represent those who are likely to require additional therapy with systemic corticosteroids. The average dose of dapsone required to control LABD in adults is 100 mg daily, but doses as high as 300 mg daily may be needed. If doses >200 mg per day are necessary, close monitoring should be undertaken. Children usually respond to a dose of 1–2 mg/kg daily.

Successful treatment of both adult and childhood LABD with antibiotics, including dicloxacillin, erythromycin, tetracycline (in those >9 years of age), and trimethoprim–sulfamethoxazole, has been reported. No specific microorganism was incriminated in these cases and therapeutic trials were empirical. A clinical trial of these relatively benign therapies may be undertaken, but no method of predicting a response has been identified. Mycophenolate mofetil, azathioprine, IVIg, and rituximab can be used as steroid-sparing agents in patients who do not respond to a combination of prednisone and dapsone or in patients with severe disease.

The natural course of the disease is characterized by persistence for several years with eventual spontaneous remission in many patients. Reported remission rates vary from 10%–60%, depending on the underlying trigger. There should be repeated attempts to taper systemic medications, on the chance that a spontaneous remission has occurred. Childhood LABD remits within 2–4 years.

Additional figures available in our eBook (see inside front cover for access code).

eFig. 31.1 Dermatitis herpetiformis. Multiple pruritic papules, many of which have central hemorrhagic crusts. *Courtesy Noah Hornick, MD, PhD, and Nan Ring, MD*.

eFig. 31.2 Multiple hemorrhagic macules on the volar aspect of the thumb. Similar lesions were present on other fingers, but typical lesions were not found elsewhere. *Courtesy Edward Cowen, MD*

eFig. 31.3 Linear IgA bullous dermatosis. The circumferential and linear vesicles and bullae are typical of this disorder.

eFig. 31.4 Linear IgA bullous dermatosis. Annular and herpetiform vesiculobullae on the face of a child.

eFig. 31.5 Linear IgA bullous dermatosis. Annular vesiculobullous lesions on the hands with central erosions and crusting. A figurate outline is seen in the area of coalescence.

Downloaded for Anonymous User (n/a) at Egyptian Knowledge Bank from ClinicalKey.com by Elsevier on March 10, 2024. For personal use only. No other uses without permission. Copyright ©2024. Elsevier Inc. All rights reserved.

eFig. 31.6 Linear IgA bullous dermatosis. A, B Annular and polycyclic plaques of the trunk in two women with the disorder.

Downloaded for Anonymous User (n/a) at Egyptian Knowledge Bank from ClinicalKey.com by Elsevier on March 10, 2024. For personal use only. No other uses without permission. Copyright ©2024. Elsevier Inc. All rights reserved.